

CASE REPORT

Acute appendicitis secondary to metastatic uterine cervix squamous cell carcinoma. Case report

Apendicitis aguda como manifestación clínica secundaria a metástasis de un carcinoma de células escamosas del cérvix. Reporte de caso

Rafael Parra-Medina^{1,2,3}, Patricia López-Correa^{1,2}, Marwil Pacheco⁴, Alfredo E. Romero-Rojas¹

¹ Oncological Pathology Group, Instituto Nacional de Cancerología, Bogotá, D.C., Colombia

² Department of Pathology, Fundación Universitaria de Ciencias de la Salud, Bogotá, D.C., Colombia

³ Research Institute, Fundación Universitaria de Ciencias de la Salud, Bogotá, D.C., Colombia

⁴ Department of Pathology and Laboratory Medicine, University of Louisville Hospital, Louisville, Kentucky, USA

Fecha de sometimiento: 25/11/2021

Fecha de aceptación: 14/07/2022

Disponible en internet: 30/03/2023

Resumen

Las neoplasias primarias y secundarias del apéndice son raras y se encuentran en aproximadamente el 1% de las muestras de apendicectomía quirúrgica. El carcinoma de células escamosas del cuello uterino (CECU) se disemina principalmente por invasión local directa de los tejidos y por vía linfática, y con menor frecuencia a través de los vasos sanguíneos. La diseminación de CECU por vía linfática ocurre de manera temprana y está presente en el 25-50% de los pacientes con carcinomas en estadio IB y II. Presentamos el caso de una mujer de 31 años con antecedente de CECU estadio IVB. La paciente recibió radioterapia paliativa (3 Gy fraccionada para un total de 30 Gy) y posteriormente quimioterapia (cisplatino 50 mg/m² IV y paclitaxel 175 mg/m² IV). Dos meses después del inicio de la terapia con radioterapia y quimioterapia, ingresó al hospital presentando dolor abdominal, fiebre y vómitos. La laparotomía reveló apendicitis perforada y un absceso intraabdominal sin evidencia de compromiso de ovario o trompa de Falopio. El examen histopatológico del espécimen extirpado evidenció un proceso inflamatorio agudo severo y la presencia de CECU. En conclusión, describimos el segundo caso de apendicitis aguda secundaria a CECU metastásico, publicado en la literatura médica. Este es un caso interesante debido a la rareza de la apendicitis aguda asociada con el cáncer de cuello uterino metastásico en el apéndice a través de los vasos linfáticos. La historia previa de CECU tuvo un papel importante para definir el diagnóstico histopatológico.

Palabras clave: apéndice, carcinoma de células escamosas, metástasis de la neoplasia

Citación:

Parra-Medina RP, López-Correa P, Pacheco M, Romero-Rojas AE. Acute appendicitis secondary to metastatic uterine cervix squamous cell carcinoma. Case report. Rev Col Cancerol. 2023;27(1):103-6. <https://doi.org/10.35509/01239015.835>

Conflictos de interés:

Los autores declaran no tener ningún conflicto de interés.

Corresponding author:

Alfredo E. Romero-Rojas
Oncological Pathology Group, Instituto Nacional de Cancerología, Bogotá, D.C., Colombia.
Email: errromero@gmail.com

Abstract

Primary and secondary neoplasms of the appendix are rare and found in approximately 1% of surgical appendectomy specimens. Cervical squamous cell carcinoma (CSCC) spreads mainly by direct local invasion of adjacent tissues and lymphatics and, less commonly, through blood vessels. The spread of CSCC via lymphatics occurs early and is present in 25-50% of patients with stage IB and II carcinomas. We present a 31-year-old female with a history of stage IVB CSCC. The patient received palliative radiotherapy (3 Gy divided for a total of 30 Gy)

and later chemotherapy (cisplatin 50 mg/m² IV and paclitaxel 175 mg/m² IV). Two months after the onset of therapy with radiotherapy and chemotherapy, she was admitted to the hospital, presenting with abdominal pain, fever, and vomiting. Laparotomy revealed perforated appendicitis and an intra-abdominal abscess with no evidence of ovary or fallopian tube compromise. Histopathological examination of the excised specimen evidenced a severe acute inflammatory process and the presence of CSCC. In summary, we describe the second case of acute appendicitis secondary to metastatic CSCC, published in the medical literature. This is an interesting case due to the rarity of acute appendicitis associated with metastatic cervical cancer in the appendix via lymphatic vessels. The history of CSCC played a significant role in defining the histopathological diagnosis.

Keywords: Appendix; carcinoma, squamous cell; neoplasm metastasis

Introduction

Primary and secondary neoplasms of the appendix are rare and found in approximately 1% of surgical appendectomy specimens (1). Appendiceal metastasis is extremely uncommon. The reported primary tumors arise from direct extension of a colon carcinoma or primary pelvic malignancy (2). On the other hand, cervical squamous cell carcinoma (CSCC) spreads mainly by direct local invasion of adjacent tissues and lymphatics and, less commonly, through blood vessels. The spread of CSCC via lymphatics occurs early and is present in 25-50% of patients with stage IB and II carcinomas. Hematogenous dissemination is the least common metastatic pathway. Hematogenous spread in carcinoma cervix is more common in the advanced stage and mostly occurs through the venous plexus or the paracervical veins. The 10-year actuarial incidence of distant metastases was 3% in stage IA, 16% in stage IB, 31% in stage IIA, 26% in stage IIB, 39% in stage III, and 75% in stage IVA (3,4). This article aims to present a case of metastatic CSCC in the appendix.

Case report

The case of a 31-year-old woman diagnosed with CSCC in stage IVB (with invasion to the peritoneum) is described. The CT scan and MRI revealed a large tumor measuring 62 x 52 x 60 mm in the cervix with extension to the isthmus, vagina, and right and left parametria. The pelvic and para-aortic lymph nodes were compromised by the tumor, as well as the peritoneum. The ovaries were free of tumors. The patient received palliative radiotherapy (three-dimensional conformal radiotherapy (3D-CRT), 3 Gy divided for a total of 30 Gy) and later chemotherapy (cisplatin 50 mg/m² IV and paclitaxel 175 mg/m² IV).

Two months after the onset of therapy with radiotherapy and chemotherapy, she was admitted to

the hospital for abdominal pain, fever, and vomiting. Laparotomy revealed perforated appendicitis with intra-abdominal abscess with no ovary or fallopian tube compromise. Thus, peritoneal lavage and appendectomy were performed.

Gross examination evidenced an appendix measuring 8.5 x 2 cm, covered by a fibrinopurulent membrane. A 1.5 cm white nodular mass was recognized as obstructing the lumen in the tip of the appendix. Microscopic examination revealed a severe acute inflammatory process and the presence of large cancerous cells characterized by hyperchromatic nuclei and irregular nuclear outline, extremely large nucleoli, scant cytoplasm, and mitotic figures in the tip of the appendix. Tumor infiltration had spread through lymphatic vessels from the mucosa to the muscularis propria. Compromise by direct invasion was not found (Figure 1A-B). Immunohistochemistry was positive for CKAE1/AE3, CK5/6, p40, p16, and p63 staining (Figure 1C-D) and negative for chromogranin and synaptophysin. The Ki67 proliferation index was approximately 70%. The patient continued to receive palliative radiotherapy and chemotherapy.

The patient provided written informed consent for the presentation of this case report.

Discussion

Appendiceal tumors are usually asymptomatic or present symptoms of acute appendicitis and even perforation, as observed in our case. Most cases are detected incidentally during surgery or histopathological examination (5). In general, primary tumor cells infiltrate the mucosa and serosa, while appendiceal metastases spread by direct local extension from the serosa to the mucosa; however, in some cases, the secondary tumor may result from lymphatic or hematogenous dissemination (6), as in our case.

Squamous cell carcinoma of the cervix metastatic to the appendix is remarkably rare. Only one case of a 43-year-old patient with stage IVB CSCC has been reported in the medical literature. This patient also presented acute abdominal symptoms (7). Recently, a similar case has been described, but in a woman with adenocarcinoma of the uterine cervix (8).

The main sites to which CSCC metastasizes are the pelvic and para-aortic lymph nodes and involve the parametria, vagina, endometrium, bladder, and rectum by direct local invasion (9). Hematogenous spread is rare. Rare cases of this blood-borne metastasis, including bone, skin, fallopian tube, muscle, kidney, and gastrointestinal tract, have been described (10-15). The differential diagnosis of metastatic appendix tumors includes neuroendocrine tumors, low and high-grade appendiceal mucinous neoplasms, mucinous adenocarcinoma, colonic-type adenocarcinoma, goblet cell carcinoma, mesenchymal tumors (GIST, desmoid, leiomyoma, leiomyosarcoma), non-carcinoid tumors (ganglioneuroma, pheochromocytoma, paraganglioma), sarcomas (HIV-associated Kaposi sarcoma, desmoplastic small round cell tumors), neuroectodermal and nerve sheath tumors (schwannoma, neurofibroma), lymphomas, and metastasis (2).

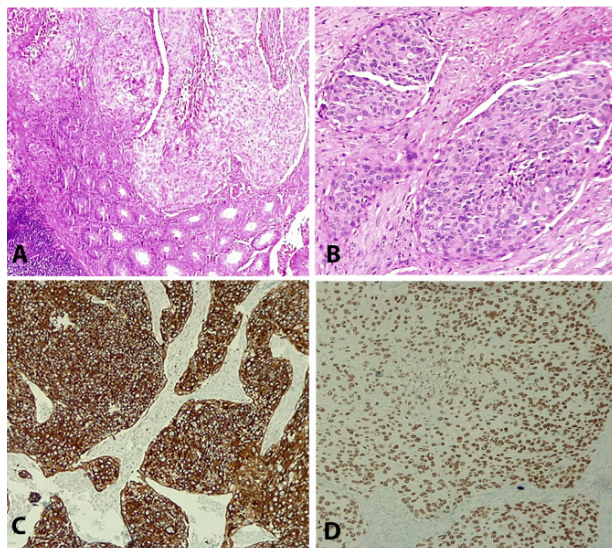


Figure 1. A-B. The appendix wall was compromised by cancerous cells characterized by hyperchromatic nuclei and irregular nuclear outline, extremely large nucleoli, and scant cytoplasm. C-D. Immunohistochemistry assay showed positivity for CK5/6 (C) and p63 staining (D).

Conclusión

Herein we describe the second case of acute appendicitis secondary to metastatic squamous cell carcinoma of the cervix published in the medical literature. Our patient exemplifies the unusual presentation of acute appendicitis associated with metastasis to the appendix via lymphatic vessels. The history of CSCC played a significant role in defining the diagnosis in our patient. Therefore, it is important to consider that metastasis to the appendix can be present especially in oncologic patients.

Referencias

1. Connor SJ, Hanna GB, Frizelle FA. Appendiceal tumors: Retrospective clinicopathologic analysis of appendiceal tumors from 7,970 appendectomies. *Dis Colon Rectum*. 1998;41(1):75-80. <https://doi.org/10.1007/BF02236899>
2. Leonards LM, Pahwa A, Patel MK, Petersen J, Nguyen MJ, Jude CM. Neoplasms of the appendix: Pictorial review with clinical and pathologic correlation. *Radiographics*. 2017;37(4):1059-83. <https://doi.org/10.1148/rg.2017160150>
3. Bhandari V, Kausar M, Naik A, Batra M. Unusual metastasis from carcinoma cervix. *J Obstet Gynaecol India*. 2016;66(5):358-62. <https://doi.org/10.1007/s13224-015-0692-y>
4. Schmid MP, Franckena M, Kirchheiner K, Sturdza A, Georg P, Dörr W, *et al*. Distant metastasis in patients with cervical cancer after primary radiotherapy with or without chemotherapy and image guided adaptive brachytherapy. *Gynecol Oncol*. 2014;133(2):256-62. <https://doi.org/10.1016/j.ygyno.2014.02.004>
5. McCusker ME, Coté TR, Clegg LX, Sobin LH. Primary malignant neoplasms of the appendix: A population-based study from the surveillance, epidemiology and end-results program, 1973-1998. *Cancer*. 2002;94(12):3307-12. <https://doi.org/10.1002/cncr.10589>
6. Li Y, Li M, Li X, Sang H. Metastasis to the appendix from adenocarcinoma of the ascending colon: A case report. *Medicine*. 2017;96(11):e6357. <https://doi.org/10.1097/MD.0000000000006357>
7. Sudirman A, Sukumar N, Davaraj B. Appendicular metastasis from carcinoma cervix. *Med J Malaysia*. 2001;56(1):100-1. PMID: [11503286](https://pubmed.ncbi.nlm.nih.gov/11503286/)
8. Fukai S, Lefor AK, Mizokami K. Laparoscopic appendectomy for metastatic cervical cancer presenting as appendicitis. *Surg Case Rep*. 2021;7(1):114. <https://doi.org/10.1186/s40792-021-01196-6>
9. Liu Z, Hu K, Liu A, Shen J, Hou X, Lian X, *et al*. Patterns of lymph node metastasis in locally advanced cervical cancer. *Medicine*. 2016;95(39):e4814. <https://doi.org/10.1097/MD.0000000000004814>

10. Cherian RM, Jeba J, Mukhopadhyay S, Backianathan S. Unusual sites of metastases of carcinoma cervix. *BMJ Case Rep.* 2017;2017:bcr2016218897. <https://doi.org/10.1136/bcr-2016-218897>
11. Deel CD, Allen RA, Holman LL, Zuna RE. Adenocarcinoma of the cervix involving the fallopian tube mucosa: Report of a case. *Diagn Pathol.* 2016;11:77. <https://doi.org/10.1186/s13000-016-0529-8>
12. Celik SU, Besli D, Sak SD, Genc V. Thyroid gland metastasis from cancer of the uterine cervix: An extremely rare case report. *Acta medica.* 2016;59(3):97-9. <https://doi.org/10.14712/18059694.2016.97>
13. Pathy S, Jayalakshmi S, Chander S, Thulkar S, Sharma MC. Carcinoma cervix with metastasis to deltoid muscle. *Clin Oncol.* 2002;14(6):447-8. <https://doi.org/10.1053/clon.2002.0106>.
14. Bazine A, Zniber HO, Ghaouti M, Bazine A, Baydada A, Sifat H. An uncommon case of renal metastasis from cervical cancer. *Cureus.* 2017;9(12):e1941. <https://doi.org/10.7759/cureus.1941>
15. Singhal A, Masood S, Mahajan C, Hadi R, Bhalla S. Gastric and colonic metastasis from cancer cervix: An unusual progression with an uncommon cause of mortality. *South Asian J Cancer.* 2015;4(1):51-3. <https://doi.org/10.4103/2278-330X.149959>